

Washington University School of  
Medicine Interlibrary Loan



ILLiad TN: 116651

**Borrower:** UUE

**Lending String:** \*WUM,UNM,MMU,KSM,KOS

**Patron:** Su, Chen

**Journal Title:** Hawaii medical journal.

**Volume:** 63 **Issue:** 6  
**Month/Year:** Jun 2004 **Pages:** 182-4

**Article Author:**

**Article Title:** wong DK; Are immune responses  
pivotal to cancer patients I

**Imprint:** Honolulu ; Hawaii Medical Association,

**ILL Number:** 7769118



**Call #:**

**Location:**

**ARIEL**

**Charge**

**Maxcost:** \$111fm

**Shipping Address:**

Eccles Health Sciences Library

University of Utah

10 N. 1900 East

Salt Lake City, UT 84112-5890

**Fax:** (801)581-3632

**Ariel:** 155.100.78.5 or 155.100.78.2

Regular

**DOCLINE NOTES:**

**Honolulu ; Hawaii Medical Association,**

---

# Are immune responses pivotal to cancer patient's long term survival? Two clinical case-study reports on the effects of *Morinda citrifolia* (Noni)

Desmond K.W. Wong MD

## Abstract

*In the State of Hawaii, there are abundant claims of benefit from cancer patients' use of the fruit juice of Morinda citrifolia (Noni). There is no well documented clinical report in peer review journals. The author here studiously examined 2 such claims through interview, review of the medical records and pathology slides. The author concludes that these cases are valuable experiences and hope to stimulate interest in Noni research as an important part of adjuvant immunotherapy for cancer.*

## Introduction

Traditionally, physicians prognosticate about cancer patient survival using statistical analysis and comparison between groups of patients at the same stage of cancer progression. As our understanding of cancer biology changes so will our treatment recommendations. Multi-center large scale prospective controlled clinical trials are needed to demonstrate on an empirical basis, the superiority of new treatments and new approaches to disease management. For solid tumors in the early stages, surgery remains the mainstay standard of care producing a more or less consistent percentage of apparent cures. Those patients who show metastases in the postoperative years eventually die from cancer regardless of additional radiation/cytotoxic chemotherapy. These modalities taken together are considered therapeutic failures especially if the original intent is for cure. For late stage disease (stage III or IV) where lymph node metastases are numerous or distant spread is present at time of surgery treatment intent clearly is palliative. For these cases, new cytotoxic drugs and combinations do not change the outcome of death due to ravages of cancer but rather, often at the expense of the quality of life the very core value of living, provide only modest prolongation in overall survival time measurements.

Recently, with the advent of anti-angiogenesis and molecular targeted therapies, NCI has boldly set a goal to eliminate suffering and premature death from cancer by the year 2015.<sup>1</sup> This will turn a common fatal

illness to the status of chronic diseases manageable like those of diabetes or heart disease. Increasingly, cancer patients are looking for answers elsewhere, mainly in alternative and complementary medicine. Noni juice from the fruit of *Morinda citrifolia* has been shown by Hirazumi and Furasawa,<sup>2</sup> to have anti-tumor effects through immunomodulating mechanisms in the laboratory. Although testimonials from patients and their families abound, no one has demonstrated in the clinic whether Noni juice actually improves long term outcome. Phase I NIH funded clinical trial with standardized Noni extract is still ongoing and results less than 2 years are encouraging, according to news released by principal investigator Dr. Brian Issell of the UH Cancer Research Center.<sup>3</sup> Here the author reports 2 clinical case studies pointing to Noni juice making a difference in terms of disease control over many years.

## Methodology

Medical records from clinics, hospitals and hospice nurses were reviewed in detail. In Case 1, X-ray and imaging studies were also reviewed with a radiologist and biopsy slides with pathologists. Apparent excellent health and multiple in-depth interviews with patient and relatives led to a clinical evaluation and a follow-up endoscopy with biopsy, 6 years after onset of symptoms, and diagnosis by the original gastroenterologist. In case 2, the study was limited to review of complete medical records from hospital and clinic, death certificate, telephone interviews with his surviving son and person who prepared Noni juice for the patient.

## Case Study Reports

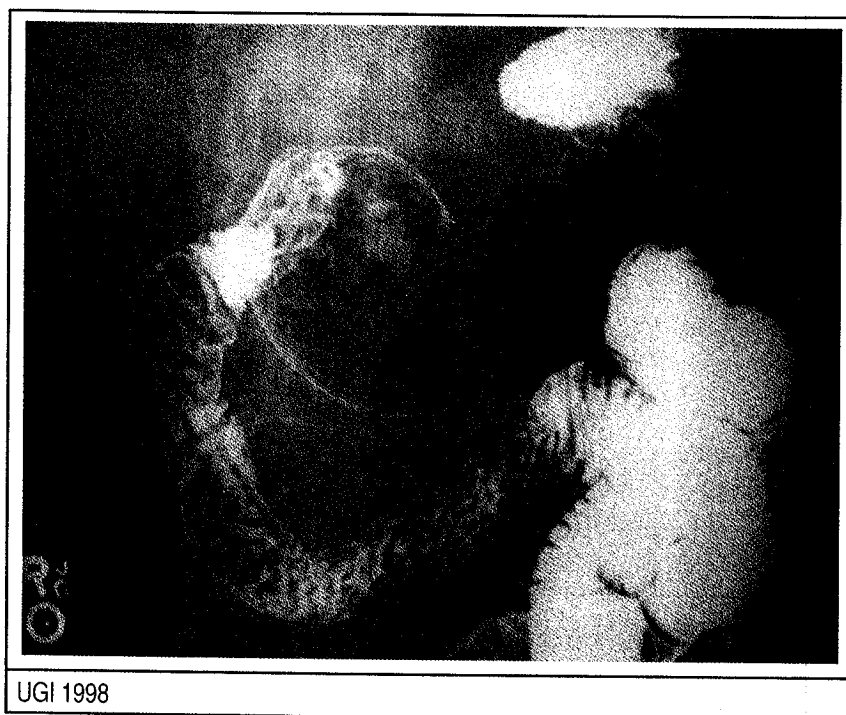
### Case 1

MC1 (*MC1- patient identification code name for protection of privacy*), at age 69 developed progressive anorexia, epigastric discomfort and weight loss. At endoscopy a pyloric channel ulcer was seen

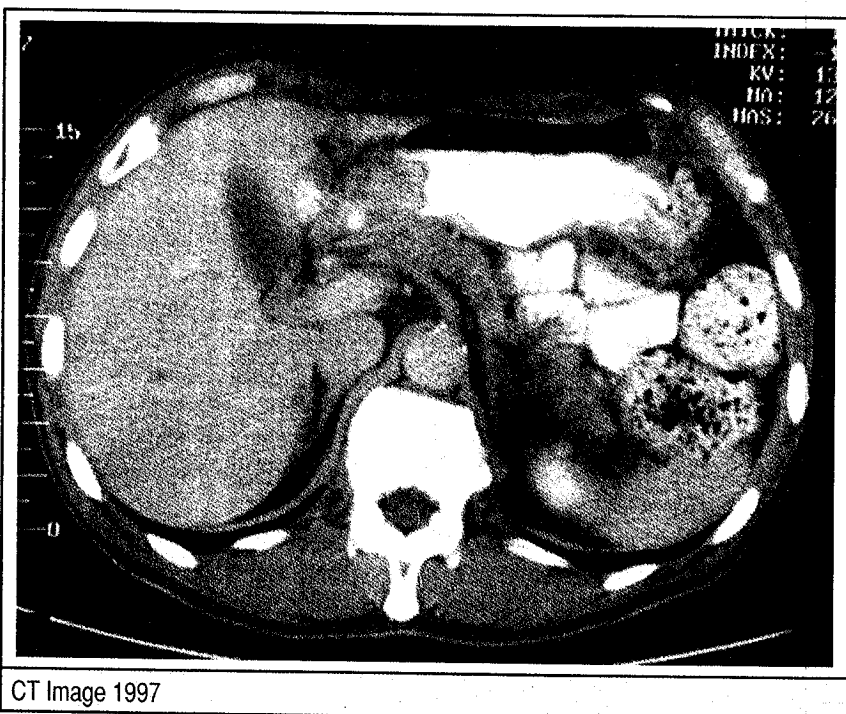
Correspondence to:  
Desmond K.W. Wong MD  
1470 Waiuanue Ave.  
Hilo, HI 96720  
Ph: (808) 961-9276  
email: kongwaiwong1@hotmail.com

and biopsy revealed poorly differentiated invasive adenocarcinoma, diffuse type with signet ring cells. He refused surgery after consulting a surgeon. He left the hospital not accepting sound advice from gastroenterologist, family physician and surgeon. He deteriorated over 2 months, becoming bedridden. His weight dropped from 165 lbs to 79 lbs and he could barely retain liquids orally with intermittent vomiting. A hospice nurse was engaged to care for him, expecting him to die in a short time. On his death bed MC1 decided to take homemade Noni juice. Remarkably he improved rapidly and within a month was able to ingest a regular diet and started to regain his weight. Soon he was able to resume his activity as a hunter and fisherman. He refused to see any regular doctor after that episode. Seven years later MC1 does not have any gastric symptoms. He had stopped taking his Noni juice regularly after the first 6 months. Prior to discharge from hospice care at one year after admission, his UGI X-ray examination was normal. On Feb 3<sup>rd</sup> 2003 almost 6 years after diagnosis, MC1 underwent his first follow-up endoscopy which revealed an atypical prepyloric ulcer. Biopsy at this time showed histology similar to his initial biopsy of cancer. To date, MC1 still persists in his decision not to consider surgical therapy but to continue self-treatment with homemade Noni juice.

Illustrations show selected images from radiographic and imaging studies of MC1.



UGI 1998



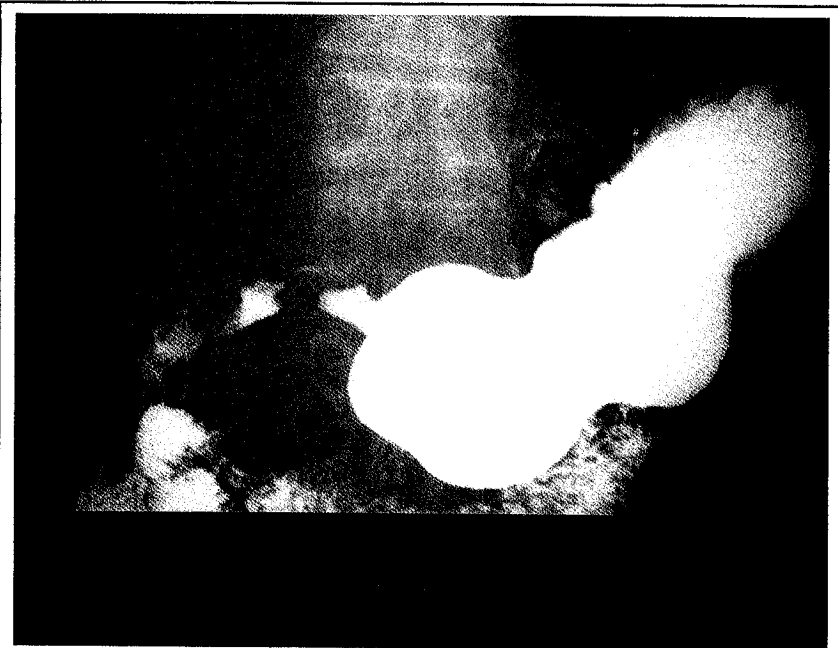
CT Image 1997

### Case 2

MC2 (MC2- patient identification code name for protection of privacy), onset at age 64 developed progressive eating difficulty and weight loss. At esophagogastrosocopy a constricting malignant looking lesion was found at the esophagogastric junction. Biopsy showed adenocarcinoma. At surgery, no gross liver metastasis was noted. A proximal gastrectomy with en bloc removal of the spleen and tail of pancreas was performed, because of firm adhesion of the rather large neoplastic tissue which had perforated through the stomach wall posteriorly to these structures. Frozen section of the esophagus resection margin showed residual cancer and the anastomosis was redone. The margin frozen section was cleared this 2<sup>nd</sup> time. No adjuvant chemotherapy therapy was available or recommended. Pathologist reported cancer infiltration through the gastric serosa without invasion of the spleen, pancreas or omentum. Metastatic carcinoma was found in 17 of 28 lymph nodes examined. Histology of the cancer was poorly differentiated adenocarcinoma, ulcerated, with marked lymphocytic and plasma cell infiltration.

MC2 developed a benign stricture at the esophago-gastric anastomosis and several biopsies were done at the time of subsequent dilations which were repeatedly required several times per year. In the ensuing 16 years his doctors could not find evidence of recurrence. Eventually at age 80 he refused to undergo any more

dilation procedures and he died. The cause of death listed in the death certificate was malnutrition due to benign stricture and history of gastric cancer. His son claims that the good outcome is attributable to patient's use of homemade Noni juice. In retrospect, surgery here must be considered curative despite the late stage of discovery. Ordinarily, surgeons would treat this as a palliative attempt, with 5 year survival statistics in the single digits. Sixteen-year disease free survival is unheard of.



UGI 1997

## Discussion

In case 1, patient had a remarkable reversal of his symptoms without surgery or other conventional therapies. Because of this fact, MC1 presents a unique opportunity for a study on immunity and cancer. The uniqueness is that researchers can completely separate the effects of immune responses together with genetic factors from those of standard therapy. If patient had surgery and/or other conventional therapies the case would render any study of this relationship difficult if not impossible. Four physicians had told patient that without surgery he would die within a few months. He took unknown risks at his peril and survived. He unwittingly became both experimenter and the subject of experimentation. Under these circumstances no rational person would choose not to have surgery in this present day and age. This index case casts doubt on our ability to prognosticate untreated gastric cancer using statistics based on pre-surgery era. Physicians may be tempted to simply assign causes for the prolonged symptom-free remission to one of luck or unknown factors though, clearly, patient's turnaround followed soon after the outset of consuming homemade Noni juice. Instead, there is a legitimate question: did the immunomodulation properties of Noni juice contribute significantly to patient's outcome?

In case 2, it is more dubious, but given the pathological findings of T3N3 (stage IV) disease, the same question remains in the minds of the author.

In March 2003, MacKie and Reid<sup>4</sup> from United Kingdom reported a fatal metastatic melanoma in the recipient of a transplanted kidney from a cadaver donor who had a history of surgical removal of a melanoma 16 years prior to donation and without evidence of recurrence at the time of death. Doctors worked hard and were able to prevent another fatal outcome on the 2nd recipient of the contra-lateral kidney which also developed metastatic melanoma. The authors recommended that history of melanoma removal, even without evidence of disease after many years, represents an absolute contraindication to organ donation since immunosuppression will unravel metastatic disease in the recipients. Today the medical community is more inclined to accept immune responses to be the major mechanism responsible for spontaneous regression or long lasting natural control of occult metastases. Here the contention is that case 2 represents an instance of micrometastases being kept in check by the immune system. Perhaps students of medical science can speculate by extrapolation a similar scenario in other in-

stances of apparent surgical cures. Along this line of reasoning it will inevitably lead us to surmise at the validity of Immunologic Surveillance of Neoplasia theory proposed by F M Burnett. Given the dismal prognosis of advanced stage cancers treated with the newest evidence-based therapeutic regimen, new approaches such as adjuvant immunotherapy are much needed.<sup>5</sup> In Hawaii, Noni is enjoying great popularity and is abundantly available. It is the author's hypothesis that immune responses, whether naturally occurring from favorable genetic factors alone and/or a result of the sum of genetic factors plus those induced by immunostimulants, do play a pivotal role in cancer patients' survival. Dr Zheng Cui of the Wake Forest University School of Medicine recently described the discovery of CR/SR strain of mice, which exhibits remarkable spontaneous rejection of Sarcoma 180.<sup>6,7</sup> To the author's delight, Dr Z. Cui and his collaborators have accepted the grave and serious responsibility to perform on this surviving patient MC1, immunological and genetic studies analogous to those done on his remarkable mice. From these studies, a new aspect of the knowledge of cancer biology in the laboratory mice and humans may possibly be found.

## Acknowledgements

Many thanks to Rhoda Noall MD and Charles Reinhold MD, of Clinical Laboratories of Hawaii, Inc., for helpful review and discussions of the biopsy histology, to George Ainge, MD of Hawaii Radiologic Inc for review of the X-ray and imaging studies, to Timothy Jahraus MD of Gastroenterologist Associates for taking special interest in the followup endoscopy in case 1. The author also gratefully acknowledges encouragement and guidance from UHM Professor Y. Hokama and retired Alec Keith (Adjunct Professor ASU, Cancer Research Institute) and lastly, the most important special thanks to Mrs. Dorothy Wong for her tolerance, time, innumerable amount of assistance, and linguistic refinements in the preparation of this manuscript.

## References

1. Eschenbach A C. JNMA 2003 July; 95(7): 637-639
2. Hirazumi A, Furasawa E. An immunomodulatory polysaccharide-rich substance from the fruit of *Morinda citrifolia*, with anti-tumor activity. *Phytother Res* 1999; 13(5): 380-7.
3. Altonn H. Honolulu Star-Bulletin 2004, Jan 8: A6
4. MacKie RM, Reid R. Fatal Melanoma Transferred in a Donated Kidney. *NEJM* 2003; 348(6): 567-8.
5. Mocellin S, Carlo R, Rossi L, Marincola FM. Adjuvant immunotherapy for solid tumors: from promise to clinical application. *Cancer Immunol Immunother* 2002; 51(11-12): 583-95.
6. Cui Z, Willingham MC, Hicks AM, Alexander-Miller MA, Howard TD, Hawkins GA, Miller MS, Weir HM, Du W, DeLong CJ. Spontaneous regression of advanced cancer: Identification of a unique Genetic determined, age-dependent trait in mice. *Proc Natl Acad Sci U S A*. 2003 May 27; 100(11):6682-7
7. Cui Z, Willingham MC. The effect of aging on cellular immunity against cancer in SR/CR mice. *Cancer Immunol Immunother*. 2004 Jan 17